CASE REPORT

Adrenal Myelolipoma in Non Functional Adenoma

Santosh Sharma*, Deepika Hemrajani, Kusum Mathur*****

ABSTRACT

Adrenal myelolipoma is rare benign neoplasm which is generally considered hormonally inactive neoplasm and composed of mature adipose tissue and normal haematopoietic cells. Adrenal cortical adenoma and myelolipoma rarely found together in the same gland. Dignosis is incidental due to its asymptomatic nature[1]. We reported a case of 71 year male with complain of lower urinary tract symptoms, who on imaging study showed an adrenal mass of size 38 x 32mm likely to be adenoma. It was detected incidentally because of its nonfunctional nature. Later on the size of mass increased and due to hemorrhage in the tumor and radiological study a diagnosis of adrenocarcinoma was given for which surgery was done and right adrenalectomy specimen sent for histopathological examination. After gross and microscopic examination reported as adrenocortical adenoma with myelolipoma which is rare to occur simultaneously. This case requires correct diagnosis and management of the adrenal mass.

Key words: Adrenocortical adenoma, Myelolipoma, Incidentaloma

INTRODUCTION

In the literature, myelolipoma was described first by the German scientist E Uber Gierke in 1904 but C Oberling was first to use the term myelolipoma in 1929.[5] Adrenal myelolipoma is a benign neoplasm composed of varying proportion of mature adipose tissue and hematopoietic elements

However sometimes adrenal myelolipomas and adrenal cortical adenoma are found together and if the cortical adenoma is non-functional then they are detected incidently[1]. Adrenal myelolipoma and non functional adrenal cortical adenoma are rare in the same gland[1]. Myelolipomas are composed of mature adipose tissue and normal haematopoietic cells. In fact, myelolipoma can now be easily detected because of improved techniques such as ultrasound, CT and MRI and widespread use of imaging[1].

CASE PRESENTATION

We report a case of 71 yr old male, presented to the S.M.S hospital OPD with complains of urinary frequency, urgency and low stream of urine. On CECT scan KUB there was right adrenal soft tissue density mass approx 38 X 32 mm? Adenoma detected incidentally. On investigating hormone study was normal. Cortisol-4.67(normal range 4.5-22.4ug/dl DHEA-82(normal range-male 80-560ug/dl, aldosterone and 24 hr. urinary metanephrine was 95.71ug (normal <350) Patient was kept under observation. After 6 month there was increase in size of right adrenal mass and haemorrhage on CT imaging study. MRI study revealed features of adrenal cortical carcinoma. Hormonal studies were within normal limits. Right adrenalectomy was performed and sent for histopathological examination.

Grossly it was a single well encapsulated, yellow, firm already cut open globular soft tissue piece measuring 4.5×3×3 cm, with capsule, yellow, lobulated soft in consistency, along with extensive areas of haemorrhage.

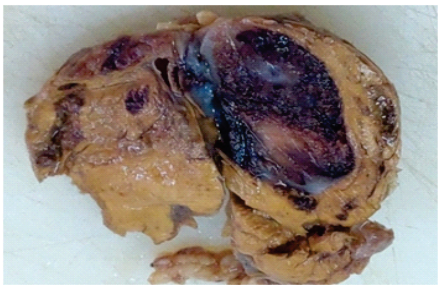

Figure 1: Gross pictures, Showing pale,gray lobulated tumor with haemorrhage and surrounded by a capsule

*Resident, **Associate Professor, ***Senior Professor
Department of Pathology, SMS Medical Collage, Jaipur, Rajasthan
Corresponding Auther:
Dr. Deepika Hemrajani
Associate Professor
389, Adarsh Nagar, Near Bees Dukan Jaipur (302004)
E-mail :deepikahemrajani@yahoo.com

Microscopically, the tumor showed capsulated, lobulated tumor composed of cells with clear cytoplasm and uniform round nucleus with no nuclear pleomorphism. No necrosis, mitosis, capsular or vascular invasion seen. Areas of osseous metaplasia, haemorrhage and hematopoietic cells seen showing presence of myelolipoma in addition.

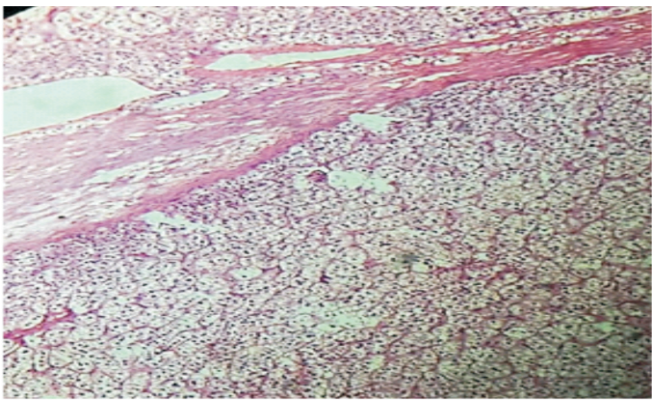

Figure 2: H/E stained Showing capsule and uniform cords of cells with pale and clear cytoplasm(100X).

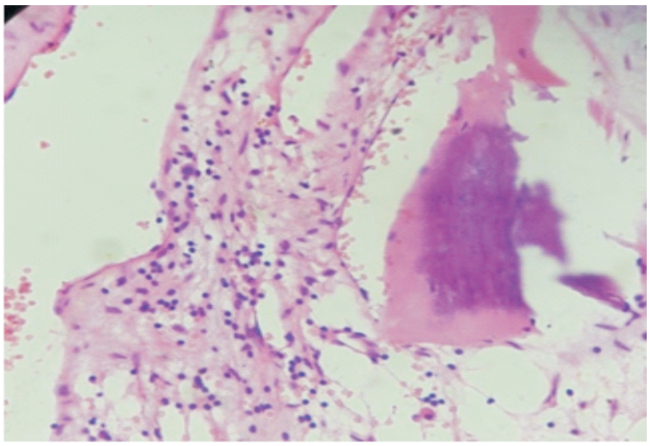

Figure 3: H/E stained showing bony trabeculae and fibrofatty tissue with haematopoitic elements(100X).

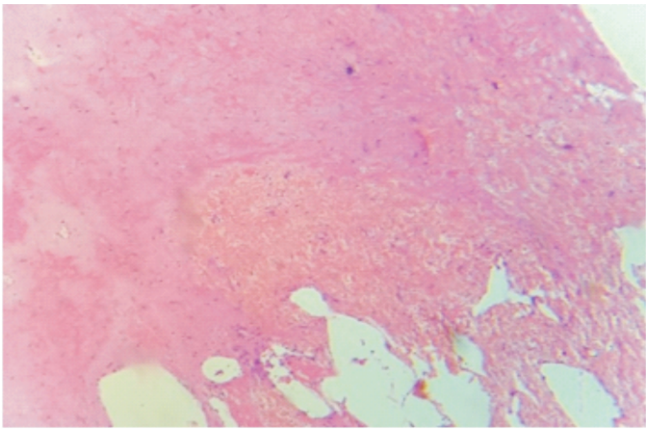

Figure 4: H/E stained showing haemorrhage(100X)

DISCUSSION

Myelolipomas are small, asymptomatic and non-functional tumors. Although the benign nature of these lesions is proved, it is unclear how these tumors develop. There are different explanations about this according to a widely accepted theory; pathogenesis of myelolipomas occurs in response to stimuli, such as, necrosis, infection or stress, reticuloendothelial cells of blood capillaries in the adrenal glands with metaplasia[2]. Myelolipomas affects both sexes equally, between the age of 50 to 70 yr[3]. Case was 71 yr old. According to reported cases, examined patients were all women. Most of the cases originated from the left side. But in our case, the tumour was located in right adrenal region. Three radiological patterns for adrenal myelolipomas are described: isolated adrenal myelolipomas, myelolipomas with haemorrhage and complex lesions with small myelolipomatous foci within other adrenal tumours (non-functional adenoma, adrenocortical adenoma, Conn's syndrome) often with extensive calcifications[4].

The dfferntial diagnosis includes; Renal angiolipoma which is more common, contains vascular and leiomyomatous elements in addition to fat. Extramedullary hematopoiesis is not encapsulated or well circumscribed and fat cells are not an integral component of the process, moreover it is symptomatic usually with splenomegaly and hepatomegaly, associated with severe anemia, myelofibrosis and myeloproliferative disorders. Retroperitoneal lipomas are rare, multiple, slow growing and abnormal proliferation of adipocytes. In Liposarcoma, fat cells are seen within the soft tissue. Diagnosis is by histologic examinatation of the tissue. Lipoblasts are often present in these cells with an abundant clear multivacuolated cytoplasm and an eccentric darkely staining nucleus that is indented by the vacuoles. For the diagnosis of these adipocytic tumors of the adrenal gland, CT and sonography are sensitive and important imaging techniques. Major difference between myelolipomas and other adrenal neoplasm is the presence of mature fat. Adrenocortical adenoma versus carcinoma - Adrenal tumors are usually not biopsied prior to surgery, so diagnosis is confirmed on examination of the surgical specimen by a pathologist. Grossly, adrenocortical carcinomas are usually large and with a tan-yellow cut surface, areas of hemorrhage and necrosis. On microscopically, the tumor usually displays sheets of

atypical cells with some likely resemble with the cells of normal adrenal cortex. The presence of invasion and mitotic activity help to differentiate small cancers from adrenocortical adenomas.

In our case there was myelolipoma which was found under a capsule, in focal area along with hemorrhage. The size of the tumors may vary from a few millimeters to 34cm and they account for about 8% of adrenal incidentalomas[5]. Myelolipoma may be associated with various adrenal pathologic conditions like adenoma, carcinoma, pheochromocytoma, idiopathic hyperaldosteronism, Addison's and Conn's disease. So diagnosis of myelolipoma is impotant as there is risk of spontaneous rupture with retroperitonal haemorrhage[6,7]. In our case there was misdiagnosis in MRI finding due to extensive haemorrhage so histopathology was required for diagnosis the of myelolipoma.

REFERENCES

1. Esma Gurbuz,1 Hamide Sayar,1 Sevgi Bakaris,1 Mehmet Fatih Inci2. 1 Department of Pathology, Sütçü İmam University, Kahramanmaraş, Turkey 2 Department of Radiology, Sütçü İmam University, Kahramanmaraş, Turkey.
2. Wani NA, Kosar T, Rawa IA, et al. Giant adrenal myelolipoma: incidentaloma with a rare incidental association. Urol Ann 2010;2:130–3.
3. Manassero F, Pomara G, Rappa F, et al. Adrenal myelolipoma associated with adenoma. Int J Urol 2004;11:326–8.
4. Yildiz L, Akpolat I, Erzurumlu K, et al. Giant adrenal myelolipoma: case report and review of the literature. Pathol Int 2000;50:502–4.
5. Amin MB, Tickoo SK, Schultz D, et al. Myelolipoma of the renal sinus. Arch Pathol Lab Med 1999;7:631–4.
6. Rocher L, Youssef N,Tasu J-P, Paradis V, Blery M. Adrenal pheochromocytoma and contralateral myelolipoma. Clin. Radiol. 2002 June;57:535-7.
7. Han M Burnett L, Fishman EK, Marshall FF. The natural history and treatment of adrenal myelolopoma. J. Urol. 1997;157:1213-6.